

# Case Study

## Reduction of Idiopathic Scoliosis and Musculoskeletal Complaints & Improved State of Well-Being in a 21-Year-Old Following Chiropractic: A Case Study & Review of the Literature

Michelle Fox, D.C.<sup>1</sup>

Jay M. Holder, DC, DACACD, FICA<sup>H</sup><sup>2</sup>

Elisa-Beth Tveitnes, D.C.<sup>3</sup>

1. Private Practice of Chiropractic, Columbia, SC
2. Holder Research Institute, Miami Beach, FL
3. Private Practice of Chiropractic, Voss, Norway

### Abstract

**Objective:** To describe reduction of adolescent idiopathic scoliosis (AIS), other spinal curves, postural faults, state of well-being and musculoskeletal complaints in a patient using Torque Release Technique® (TRT) protocol.

**Clinical Features:** A 21-year-old female with complaints low back pain with radiating numbness into legs and feet when lying supine and headaches. The patient's diagnosis of AIS was confirmed via radiographic imaging. Radiographs showed a C-shaped thoracolumbar levoscoliosis of 20°, thoracic hyperkyphosis of 63°, lumbar hyperlordosis of 70°, and postural fault of high right ilium height of 5mm. Exam revealed vertebral subluxations using the TRT protocol, and Dysautonomia via COREscore™ subluxation analysis by way of thermal scan, surface electromyography, and heart rate variability.

**Intervention and Outcomes:** Post- x-rays taken after five months of care (62 visits) showed reduction of the scoliotic curve from 20° to 12.5°, reduction of thoracic hyperkyphosis from 63° to 40°, reduction of lumbar hyperlordosis from 70° to 65° and improvement in postural fault of high right ilium from 5mm to 2mm. Final subluxation analysis after seven months of TRT care showed an overall COREscore™ improvement of 19% from 66/100 to 85/100. She experienced improvement of over 50% in state of well-being and physical complaints through interpretation of Revised Oswestry Back Pain Disability Index (RODI) which was initially 32% and at the end of care was 14%.

**Conclusion:** The results of this case study suggest that chiropractic adjustments using a non-linear tonal model, Torque Release Technique®, can help reduce the scoliotic curvature of the spine of a female with adolescent idiopathic scoliosis, improve other attending or compensatory curves and postural faults, as well as improve state of well-being and musculoskeletal complaints.

**Key Words:** Torque Release Technique®, Integrator™, scoliosis, vertebral subluxation, postural faults, COREscore™, HRV, sEMG, NCM, headaches, adjustment, chiropractic

### Introduction

#### Scoliosis

Scoliosis is a derivation from the Greek word skolios, meaning twisted or crooked. Any lateral curvature of the spine >10° in coronal plane is called a scoliosis. Patients with scoliosis are classified by types according to age of onset,

etiology and severity of curve. Adolescent idiopathic scoliosis (AIS) is a spinal curvature presenting at or about the onset of puberty and before maturity.<sup>1</sup> It is a common disease with a prevalence of 0.47–5.2%.<sup>2</sup> Prevalence and curve severity are

higher for girls than for boys, and the female to male ratio increases with increasing age of the child.<sup>2</sup> Adult spine deformity is a significant health issue within the aging population in both the United States and the world communities.<sup>3</sup>

The spinal curvature is measured using Cobb's method. The end vertebrae are located on the AP x-rays, and lines are drawn on their appropriate endplates. Perpendiculars are erected to the endplate lines, and the intersecting acute angle is measured.<sup>1</sup> The intra- and inter-observer reliability of the Cobb measurement has been proven to be good.<sup>4</sup>

Primary headaches are one of the most common ailments, with a prevalence in the general population of about 16%, and epidemiological studies report that 5% of adults suffer from headaches on a daily basis.<sup>5</sup> Three types of headaches have been shown to account for the majority of these episodes: migraine, tension-type, and cervicogenic which is associated with neck pain and dysfunction.<sup>5</sup>

#### *Insight™ Subluxation Station*

The Insight™ Subluxation Station was used to measure the patients' baseline health status and to provide a means by which clinical outcomes can be objectively compared to determine if chiropractic care showed improvements in physiological function and state of well-being in this case study. NCM, sEMG and HRV which make up the COREscore™ in the system of the Insight™ from Chiropractic Leadership Alliance (CLA), provides clinical data for comparison and re-evaluation of the overall status of the patient's general health and well-being<sup>6</sup> while under chiropractic care.

According to CLA,<sup>7</sup> HRV helps to determine a patients' ability to adapt to stress (physical, chemical or emotional) in their life. It does this by looking at the timing of pulse, and determining the balance and tension within the nervous system.<sup>7</sup> Measuring HRV using the Pulse Wave Profiler (PWP) is a simple, sensitive and non-invasive analysis based on beat-to-beat alterations in heart rate. HRV is also an indicator of the level of balance between the sympathetic and the parasympathetic divisions of the autonomic nervous system, and its expression of stress or tension has been associated with discrete changes in autonomic function.<sup>8</sup> During this study the patient was seated in a relaxed position while HRV was monitored for five minutes.

Evaluation of paraspinous muscle tone is an important part of the chiropractic assessment.<sup>7</sup> Surface EMG is a scanning procedure employing hand-held sensors which are placed over the skin of paraspinous muscle tissue. It is used to collect and record electrical potentials associated with muscle activity. The muscular activity of various spinal segments is then analyzed by a software program and compared to a normative database. Surface EMG has been shown to be an objective measurement of change in a patient's progress.<sup>7</sup> The Insight™ sEMG was used to measure paraspinous muscle tone to determine if chiropractic care resulted in improvements in this case study.

Thermal scan (NCM) analysis is a measurement of infrared

heat emission from the skin. In normal individuals, paraspinous temperatures should be segmentally symmetrical. Thermal asymmetries indicate abnormal autonomic nervous system regulation associated with vertebral subluxation.<sup>9</sup>

The COREscore™, which is made up of the three-forementioned spinal-neural tests, quantifies a Neural Efficiency Index and demonstrates how stress is impacting a persons' overall health and well-being by detecting where and how deep problems are being caused by the three main stresses from the environment.<sup>8</sup> Wellness results range from a score of 80-100.

#### *Torque Release Technique® , A Non-Linear Tonal Model*

Torque Release Technique® was created by Jay M. Holder, DC. TRT incorporates 15 diagnostic indicators from seven long standing chiropractic techniques, as well as its own diagnostic protocol to provide a non-linear (randomized) differential diagnosis for primary subluxation, embracing the tonal model of chiropractic.<sup>10</sup> D.D. Palmer stated he discovered chiropractic on tone. According to Holder, the idea behind the primary subluxation is that at any given moment, patients present with multiple subluxation but there can only be one primary subluxation at a time manifest among them. All other subluxations that are concomitantly expressed are secondary or tertiary subluxations, which are compensatory to the primary subluxation.

This technique is considered tonal because it relies upon "real-time", or non-linear interaction with the nervous system to determine what, where, when and what subluxations not to adjust in order to best reduce abnormal torsional and tensile forces affecting the Cranio-Spinal-Meningeal Functional Unit™ (CSMFU) as a whole. The primary structures involved in modulating the tension - or "tone"- of the nervous system are the dural attachments to the vertebrae and cranial vault encasing the central nervous system. For this reason, segments with direct dural attachments are chiropractic's most common listings. The adjustment of primary subluxations in this case were made through use of an adjusting device called the Integrator™. The Integrator™ possesses a pre-cocking, pressure sensitive simulated pisiform tip with an automatic release mechanism,<sup>11</sup> an adjustable directional torque setting, true force adjustment and recoil component; for the purpose of reproducing the specific chiropractic adjustment by hand known as Toggle Recoil with The Torque.<sup>12</sup> The Integrator™ is the only adjusting instrument that provides a 3-dimensional thrust for the multiple vectors (LOD) manifest among three and four letter listings of the subluxation.

#### **Review of Literature**

A pilot study published in 2006 explored the effectiveness of chiropractic manipulation with AIS patients.<sup>13</sup> Increasingly, adults and children are seeking complementary and alternative therapy, including chiropractic treatment, for a wide variety of health concerns. Approximately 2.7 million patient visits are made to American chiropractors each year for scoliosis and scoliosis-related complaints.<sup>13</sup> According to the 2006 study, chiropractic manipulation and other chiropractic approaches used with AIS patients are based largely on historical and anecdotal information without any scientific evidence.<sup>13</sup>

In 2007 a systematic literature review of nonsurgical treatment in adult scoliosis was done, saying conservative care in general may be a helpful option in the care of adult deformity, but evidence for this is lacking.<sup>3</sup>

An internet search of published literature for peer reviewed citations pertaining to chiropractic care and scoliosis within PubMed, Index to Chiropractic Literature and Mantis databases resulted in seventeen case studies that have been published since 2007. There is a growing body of evidence suggesting chiropractic care may be beneficial for many people suffering from scoliosis, and as of this writing, Holder Research Institute provides online pre- and post- x-rays demonstrating complete scoliosis reversal using TRT in patients of various ages and gender, averaging as little as four months between pre- and post- x-rays.<sup>14</sup>

In 2008 Chen and Chiu published a case study with a 15-year-old female patient.<sup>15</sup> The Cobb angle was 46° and surgical intervention was suggested to prevent significant deformity. This patient was treated with spinal manipulation two times per week for 6 weeks, which was gradually decreased in frequency. After 18 months of consecutive treatment, follow-up radiographs and examinations were conducted. The Cobb angle had decreased by 16°, and surgical intervention was avoided.<sup>15</sup>

Khauv and Dickholtz presented a case study in 2010 with another 15-year-old female patient. She had scoliosis with a Cobb angle of 44°. She received National Upper Cervical Chiropractic Association (NUCCA) care for 5 months and the Cobb angle was reduced to 32°.<sup>16</sup>

A 2012 published case study of a 21-year-old female with scoliosis demonstrated improvement in scoliotic curve after chiropractic care utilizing Diversified technique and Chiropractic Biophysics (CBP) technique.<sup>17</sup>

A 2011 published case study by Chung and Salminen demonstrated that upper cervical adjustments improved scoliosis in a 10-year-old female. An independent medical radiologist found and confirmed that the patient's 35° thoracolumbar curve was reduced by 10° after chiropractic care.<sup>18</sup>

Another study from 2011 by Morningstar, regarding a 14-year-old female, achieved improved outcomes following chiropractic care. These improvements were evident at long-term follow-up while performing home-based rehabilitation. Outcome measures also improved at follow-up after 4 years with the Cobb angles reducing thoracic curve from 24° to 12°, and lumbar curve from 17° to 4°.<sup>19</sup>

A case report from Wendland-Colby and Addison in 2012 demonstrated improvement in a 11-year-old female scoliosis patient. The patient received diversified chiropractic adjustments and gravity assisted traction on a weekly basis, with a total of 31 visits over a three-month period.<sup>20</sup>

Morningstar, Strauchman and Gilmour published a case report in 2004 using Pettibon corrective procedures on a 20-year-old female patient. This reduced the thoracolumbar scoliosis by 15° (43%) after six weeks of care.<sup>2</sup>

A 2013 case study by Jones described a 14-year-old female with scoliosis. The patient was under chiropractic care for 13 weeks, which consisted of 15 adjustments utilizing Thompson technique. Pre- and post- radiographs revealed a reduction in the Cobb angle of the patient's curvature.<sup>22</sup>

Dovorany, Morningstar, Stitzel and Siddiqui published a 2014 case report with identical female twins. Both girls had a thoracolumbar scoliosis, one with 47° Cobb angle and the other 37° Cobb angle. At the two-year follow up appointment, when both twins had reached skeletal maturity, following the two years of chiropractic corrective treatments both girls demonstrated reduced Cobb angles by the amount of 19° and 15°, respectively. They also avoided the other recommended treatment options of bracing and surgery.<sup>23</sup>

In a narrative review of upper cervical procedures in 2015, Woodfield et al. described two cases with scoliosis.<sup>24</sup> A 10-year-old girl with a 35° scoliosis received National Upper Cervical Chiropractic Association (NUCCA) care, and after twenty-five weeks demonstrated a 10° reduction in the Cobb angle which was confirmed by an independent medical radiologist. Similarly, another NUCCA study showed a reduction from 44° to 32° in Cobb angle, measured after 20 weeks of care.<sup>24</sup> Both case studies showed that chiropractic care was helpful for scoliosis of a more severe degree.<sup>23,24</sup>

In 2015 Woggon and Woggon did a survey to detect side effects of chiropractic scoliosis treatments. They found that mild side effects were common, although the frequency was lower than the reported average for chiropractic interventions. The rate of moderate side effects reported was one per 533 visits involving the care of 189 scoliosis patients surveyed from 9 chiropractic offices over a timeframe of one calendar year.<sup>25</sup>

Ray, Knowles and Knowles describe a case study with a 75-year-old male. The patient received Network Spinal Analysis™ care under standard protocols for a two-year period. The Cobb Angle reduced to three degrees at one year, and less than one degree after two years of care.<sup>26</sup>

Several published case studies have compared scoliosis and conservative treatment. A review article from 2016 in Asian Spine Journal concluded that postural rehabilitation using scoliosis-specific exercises was effective in the treatment of adolescent idiopathic scoliosis patients when incorporated into daily life.<sup>27</sup>

The medical model of care for scoliosis suggests that spinal fusion is indicated when the deformity exceeds 45°.<sup>28</sup> Treatment is thus necessary to prevent and/or reduce the progression of curvatures.

Conservative treatment of adolescent idiopathic scoliosis includes observation, scoliosis-specific exercises (SSE) and bracing. There is increasing evidence suggesting that SSE and brace treatment can significantly limit the progression of spinal curvatures.<sup>28</sup> In growing adolescents with curvatures more than 20°, bracing is indicated, according to Sy, Bettany-Saltikov and Moramarco and should be used in conjunction with SSE.<sup>28</sup> The effectiveness of bracing varies according to the type of brace applied to the patient. Recently it has also

been reported that high quality bracing can also reduce curvatures exceeding 45° in over 70% of growing adolescents. This knowledge might increase the threshold of surgical indications to beyond 50° or above in the near future.<sup>28</sup>

Two Japanese researchers found a high incidence of scoliosis in children with tension-type headache. The incidence of scoliosis in their patients with headache was estimated to be approximately 19% (2/15 in males and 3/11 in females). There was no characteristic pattern of scoliosis; two had left scoliosis, two had right scoliosis and one patient had an S pattern. It is reported that the general incidence of scoliosis in school children is less than 5% in Japan. Therefore, the incidence of scoliosis in children with a tension headache appeared to be higher than that in general population.<sup>29</sup>

## Case Report

### History

A 5'7", 115lb. 21-year-old female, presented for care to a chiropractic clinic. The patient's complaints included low back pain with radiating numbness into legs and feet when lying supine and headaches every day prior to initial exam. She reported that her problems began four years earlier while she was cheerleading and doing gymnastics in high school. As reported on her RODI, standing, sitting, bending and lifting movements were provocative of her pain. She rated her initial low back pain as 8/10 on the pain scale (0 being no pain, 10 being the worst pain experienced), on average as 5/10 and at best it was 0/10. When lying supine for more than 5 minutes or sitting for more than 1 hour the patient experienced numbness in her legs and feet. Additionally, she complained of pain "poking" into her abdomen while lying on her right side, and bilateral suboccipital headaches at least three times per week.

### Initial Chiropractic Exam

Objective data included a plain film scoliosis series provided by the patient from a different provider, which had been taken 11 months prior to initial visit and revealed a C-shaped thoracolumbar levoscoliosis of 20° with convex at T12-L1 (fig.1), thoracic hyperkyphosis of 63° (fig.3), lumbar hyperlordosis of 70° (fig.5), and high right ilium height of 5mm (fig.1). Additional objective testing resulted in an NCM result of 35 (fig.7), sEMG result of 70 (fig.8), and HRV of 82 (fig.9), culminating in a COREscore™/Neural Efficiency Index of 66/100 (challenged) (fig.10). Palpation revealed misalignments and tenderness at multiple spinal segments, hypertonicity from L2-L3 on the left, and decreased prone hip extension on the left. TRT indicators of subluxation present were a functional leg length reflex™ (FLLR) on the right and heel tension on the left. However, because TRT is a non-linear intervention, the 15 indicators of subluxation and FLLR are reassessed prior to every adjustment during a visit.<sup>11</sup>

Restricted active ranges of motion (AROM) were observed in the following areas: cervical extension, right and left cervical lateral flexion, and right lumbar rotation with pain into the right scapula. Postural analysis revealed right lateral cervical translation, right cervical rotation and left high shoulder. On a scale of 0-10 (0=none, 10=extreme), the patient subjectively

rated her stress levels as 7/10 personal, 7/10 at home and 8/10 at work/school. On a scale of 0-10 (0=very poor, 10=excellent) the patient rated her general health as 6/10, eating habits 5/10, sleep 6/10 and exercise 6/10.

### Intervention and Outcomes

TRT adjustments using the Integrator™ were given throughout a seven-month period using the TRT protocol. Patient was adjusted initially with a frequency of three visits per week for four weeks, two visits per week for six weeks, then three visits per week for the remainder of care.

New x-rays were taken in March 2016 at the same facility as original series, after 5 months of care (62 visits) (fig.2,4,6), and a showed reduction of the scoliotic curve from 20° to 12.5°, reduction of thoracic hyperkyphosis from 63° to 40°, reduction of lumbar hyperlordosis from 70° to 65° and improvement in postural fault of high right ilium from 5mm to 2mm.

Initial sEMG and thermography scans revealed areas of asymmetrical motor and autonomic function respectively throughout the entire spine (fig.7,8). These spinal-neural exams, including HRV (fig.9), were repeated at each reassessment visit (12, 24, 36, 49, 62 and 86) (fig.16). After seven months of chiropractic care, at the patient's last visit, the HRV measured 84, increased from initial 82. The sEMG result was 81, increased from 70, and thermal scan result was 91, an increase from 35. COREscore™ result on last visit 85/100, an increase from initial visit at 66/100 (fig.11-14). The progress over the seven months of care as described in figure 16 shows that the patient had an immediate improvement after the first month of care at 3 visits per week, then a slower progression at 2 visits per week, but later showing continued improvements with return to 3 visits per week over time.

Interpretation of Revised Oswestry Back Pain Disability Index (RODI) showed improvement of over 50% (32% initial and 14% final) in state of well-being and physical complaints. At three months of care the patient was able to sleep throughout the night without pain and stand for more than one hour without pain.

Additionally, at visit 24, subjective questionnaire revealed much improvement from the initial exam (table 1). The patient rated her clinical symptoms at re-examinations throughout care on a scale of *same, mild improvement, moderate improvement, much improvement* or *totally better*. The symptom of radiating low back pain was rated as *much improvement* for every month, except for the first reassessment then it was rated *mild improvement*. The patient's symptom of numbness in legs while lying supine was rated with *moderate improvement* from reassessment to reassessment, except third reassessment it was rated *mild improvement*. Headache frequency fluctuated with *mild, moderate* and *much improvement* ratings and she reported a total of 21 headaches over the course of seven months of care. Pain while sleeping was rated mostly *totally better* at every reassessment, except fifth where it was rated *much improvement*. Overall, the patient had much improvement of her musculoskeletal complaints.

## Discussion

### *Vertebral Subluxation*

Regardless of the technique used, a majority of chiropractors are focused on detecting and correcting vertebral subluxations to improve function.<sup>30</sup> The original vertebral subluxation complex model consisted of five components: kinesiopathology, neuropathology, myopathology, histopathology, and biochemical alterations. The model that is the most current consists of nine components and aspects: kinesiology, neurology, myology, connective tissue pathology, angiology, inflammatory response, anatomy, physiology, and biochemistry.<sup>30</sup> According to the World Health Organization (WHO) a subluxation is defined as "A lesion or dysfunction in a joint or motion segment in which alignment, movement integrity and/or physiological function are altered, although contact between joint surfaces remains intact. It is essentially a functional entity, which may influence biomechanical and neural integrity."<sup>31</sup> The vertebral subluxation complex (VSC) is defined as "A theoretical model and description of the motion segment dysfunction, which incorporates the interaction of pathological changes in nerve, muscle, ligamentous, vascular and connective tissue."<sup>33</sup>

### *Primary Subluxation*

Torque Release Technique® considers the primary subluxation a neurological lesion and locates the primary subluxation and its LOD listing through a method of differential diagnosis, by identifying abnormal tension within the Cranio-Spinal-Meningeal Functional Unit™ (CSMFU) and evaluating changes in nerves, muscles, ligamentous, vascular and connective tissues. The Integrator™ was used "to introduce an adjustive force into the body that will allow for the restoration of normal tone within the functional unit (CSMFU) of the spine and nervous system."<sup>32</sup>

A TRT chiropractic adjustment is based on the premise that deviations in normal Hz frequency of nerve transmission (nerve interference) throughout the nervous system (separation of wholeness), which are manifested by cord tension or torsion transmitted through spinal dural attachments caused by primary subluxations, would necessitate a 3-dimensional toggle recoil adjustment, applied through appropriate correctional vectors (LOD) with intent to restore normal Hz frequency. The adjustment is delivered with low mass, high velocity and concomitant recoil @ 1/10,000<sup>th</sup> of a sec with or without directional torque using the Integrator™.<sup>32</sup>

Torque Release Technique® has had positive outcomes in case studies of ADHD, autisms, dyslexias, depression, migraine headaches and lifestyle issues,<sup>6,32,33</sup> and in comprehensive research which has been published regarding state of well-being, compulsive disorders, reward deficiency syndromes, depression, anxiety and addictions.<sup>34</sup> In addition, published randomized clinical trials on anxiety, depression, state of well-being and addiction treatment have shown good results using TRT.<sup>35</sup>

### *Dural Attachments*

The improvement in sEMG and thermal scan patterns

demonstrate that the pattern of vertebral subluxation was reduced in this particular case study. Upper cervical chiropractic techniques base their technique on the Dentate Ligament Cord Distortion Hypothesis, posited by Grostic in 1986.<sup>24</sup> It provides a possible explanation for spinal cord deformation produced when the atlas is positioned abnormally.<sup>24</sup> This distortion mechanism appears supported by cord deformation observed in MRI studies of the upper cervical spine.<sup>24</sup> This supports the tonal technique's theory of dural attachments and physiological changes.

When scoliosis progresses to a Cobb angle of or exceeding 45°–50° in growing children, spinal fusion surgery is often recommended.<sup>27</sup> This is because curves greater than 50° at skeletal maturity are reported to progress an additional 20°–30° over the subsequent 30–40 years' period.<sup>27</sup> For the patient to have the option to avoid a surgery is important. It is therefore of great significance that this case study in addition to past case studies as mentioned previously have shown that different types of chiropractic techniques have the ability to reduce the scoliotic curvatures of patients.<sup>15,16,18,19,21,23,24</sup>

TRT, being a tonal technique, may help improve AIS using less force and greater reproducibility than other techniques, and also reduce the physical complaints concomitant with scoliosis.<sup>18,22,26</sup> In addition to chiropractic care, research has reported efficiency of scoliosis-specific exercises and bracing. Some case studies using chiropractic care also included home-exercises with good results.<sup>17,19,21,22,26-28</sup>

### *Limitations*

The patient in this case study had several complaints upon presentation for chiropractic care, therefore, it is difficult to define the cause and effect relationship of those complaints due to her external environment. It is important to note that at 3<sup>rd</sup> month under care, patient reported that when she returned from winter break to her apartment, it was overrun with black mold which was present throughout her bedroom, closets and bathroom. The patient stayed in that apartment for the remainder of her chiropractic care, which ended due to moving out of state for work, and therefore further assessment of any additional improvements from continued intervention and treatment of her scoliosis were no longer possible.

### **Conclusion**

This case study supports the observation that a non-linear tonal chiropractic technique such as Torque Release Technique®, can markedly reduce an adolescent idiopathic scoliotic curve, improve thoracic kyphosis, lumbar lordosis and postural faults, improve COREscore™/Neural Efficiency Index, state of well-being, and musculoskeletal complaints. These results suggest more research is warranted.

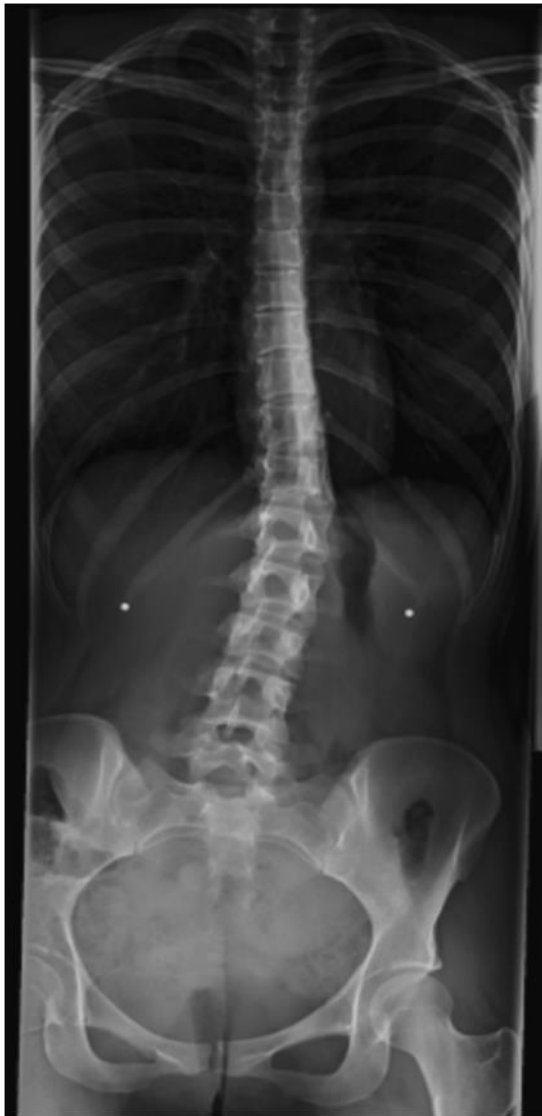### **References**

1. Yochum TR, Rowe LJ. Essentials of skeletal radiology. Third Edition. Lippincott Williams and Wilkins. 2005.
2. Konieczny MR, Senyurt H, Krauspe R. Epidemiology of adolescent idiopathic scoliosis. J Child Orthop (2013)7:3–9.

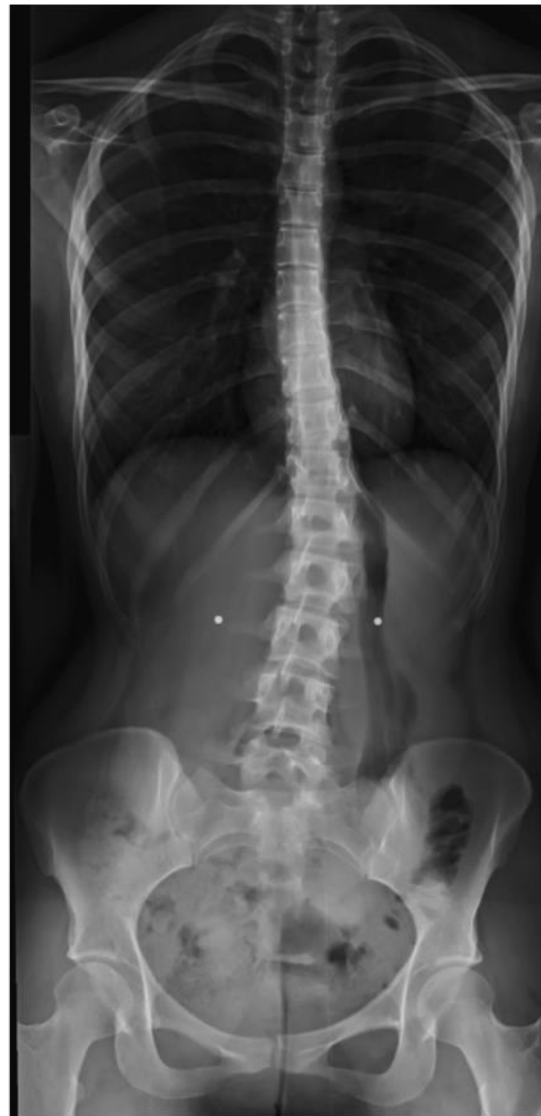3. Everett CR, Patel RK. A systematic literature review of nonsurgical treatment in adult scoliosis. *Spine* 2007 Sep 1;32(19 Suppl):S130-4.
4. Cracknell J, Lawson DM, Taylor JA. Intra- and inter-observer reliability of the Cobb measurement by chiropractic interns using digital evaluation methods. *J Can Chiropr Assoc* 2015; 59(3).
5. Haas M, Spegman A, Peterson D, Aickin M, Vavrek D. Dose response and efficacy of spinal manipulation for chronic cervicogenic headache: a pilot randomized controlled trial. *Spine J.* 2010 Feb;10(2):117-28.
6. Mahanidis T, Russel D. Improvement in quality of life in a patient with depression undergoing chiropractic care using Torque Release Technique: A case study. *J Vert Sublux Res:* 2010(Jan:31).
7. <http://www.subluxation.com/>
8. Kathrotia R, Singh Y, Goel A, Patil P. 'Is going through clinical test a headache?' An HRV study and descriptive report of subjective experience of undergoing EEG testing. *Ann Neurosci.* 2016 Mar 11;23(1):13-17.
9. Kelly S, Boone WR. Clinical application of surface electromyography as an objective measure of change in the chiropractic assessment of patient progress: A pilot study. *J Vert Sublux Res:* 1998; 2(4):1-7.
10. Shriner S. A review of Torque Release Technique®. *Ann Vert Sublux Res.* 2012 Sum;2012(3).
11. Holder, J, et al. Life University Torque Release Technique® Manual. 2011.
12. Stephenson RW. Chiropractic Text Book. Davenport: Palmer School of Chiropractic. 1927:305-7.
13. Rowe et al. Chiropractic manipulation in adolescent idiopathic scoliosis: a pilot study. *Chiropr & Osteopat:* 2006(13:1).
14. Holder Research Institute, Torque Release Technique. (cited Jun 2017): <http://www.torque-release.com/xrays.php>
15. Chen K, Chiu E. Adolescent idiopathic scoliosis treated by spinal manipulation: A case study. *J Altern Complement Med.* 2008 Jul;14(6):749-51.
16. Khauv KBK, Dickholtz MD. Improvement in adolescent idiopathic scoliosis in a patient undergoing upper cervical chiropractic care: A case report. *J Pediatr Matern & Fam Health - Chiropr.* 2010 Fall;2010(4).
17. Nektalov B. Improvement in a patient with scoliosis undergoing chiropractic care: A case study. *J Pediatr Matern & Fam Health - Chiropr:* Win 2012(2012:1).
18. Chung J, Salminen B. Reduction in scoliosis in a 10-year-old female undergoing upper cervical chiropractic care: A case report. *J Pediatr Matern & Fam Health - Chiropr:* Win 2011(2011:1).
19. Morningstar M. Four-year follow-up of a patient undergoing chiropractic rehabilitation for adolescent idiopathic scoliosis. *J Pediatr Matern & Fam Health - Chiropr:* Spr 2011(2011:2).
20. Wendland-Colby C, Addison DL, Curve improvement in a patient with adolescent idiopathic scoliosis following chiropractic care: A case report. *J Pediatr Matern & Fam Health - Chiropr:* Sum 2012(2012:3).
21. Morningstar M, Strauchman MN, Gilmour G. Adolescent idiopathic scoliosis treatment using Pettibon corrective procedures: A case report. *J Chiropr Med: Sum* 2004(3:3): 96-103.
22. Jones D. Reduction in adolescent idiopathic scoliosis following chiropractic care: A case study. *J Pediatr Matern & Fam Health - Chiropr.* 2013 Spr;2013(2).
23. Dovorany B, Morningstar M, Stitzel C, Siddiqui A. Results of chiropractic scoliosis rehabilitation treatment at two years post-skeletal maturity in identical female twins. *J Body Mov Ther.* 2015;19(4):592-6.
24. Woodfield HC et al. Craniocervical chiropractic procedures - a précis of upper cervical chiropractic. *J Can Chiropr Assoc.* 2015 Jun;59(2):173-92.
25. Woggon AJ, Woggon DA. Patient-reported side effects immediately after chiropractic scoliosis treatment: a cross-sectional survey utilizing a practice-based research network. *Scoliosis* 2015;10(1).
26. Ray K, Knowles D, Knowles R. Reduction of a lumbar scoliosis and improved cervical curve in a geriatric patient following Network Spinal Analysis™ care: A case study. *Ann Vert Sublux Res: Spr* 2013(2013:2).
27. Weiss HR, et al. Postural rehabilitation for adolescent idiopathic scoliosis during growth. *Asian Spine J.* 2016;10(3):570.
28. Sy N, Bettany-Saltikov J, Moramarco M. Evidence for conservative treatment of adolescent idiopathic scoliosis - update 2015(mini-review). *Curr Pediatr Rev.* 2016;12(1):6-11.
29. Yamamoto T, Narai S. A high incidence of scoliosis in children with tension-type headache. *Pediatr Int.* 2004;46(6).
30. Kent C. Models of vertebral subluxation: a review. *J Vert Sublux Res.* 1996(1:1):11-17.
31. World Health Organization. WHO guidelines on basic training and safety in chiropractic. Geneva 2005.
32. Hodgson N, Fox M. Improvements in signs and symptoms of ADHD, migraines and functional outcomes while receiving subluxation based Torque Release chiropractic and cranial nerve auriculotherapy. *Ann Vert Sublux Res: Dec* 2014(2014:4).
33. Pauli Y. Quality of life improvements and spontaneous lifestyle changes in a patient undergoing subluxation-centered chiropractic care: a case study. *J Vert Sublux Res:* 2006(Oct:11).
34. Blum K, Braverman E, Holder J et al. Reward deficiency syndrome: A biogenic model for the diagnosis and treatment of impulsive, addictive, and compulsive behaviors. *J of Psychoactive Drugs.* 2000 Nov;32(2):S59-60.
35. Holder J, Duncan R, Gissen M, Miller M, Blum K. Increasing retention rates among the chemically dependent in residential treatment: Auriculotherapy and subluxation-based chiropractic care. *Mol Psychiatry.* 2001 Feb;6(S1); part 2, abstracts, S8.

| After 24 adjustments               | Same | Mild improvement | Moderate improvement | Much improvement                      | Totally better |
|------------------------------------|------|------------------|----------------------|---------------------------------------|----------------|
| Radiating low back pain            |      |                  |                      | with 0/10 pain on date of exam        |                |
| Numbness in legs when lying supine |      |                  |                      | only 1 occurrence since start of care |                |
| Frequent headaches, 3 or more/week |      |                  |                      | total of 5 headaches reported         |                |
| Pain while sleeping                |      |                  |                      | ✓                                     |                |

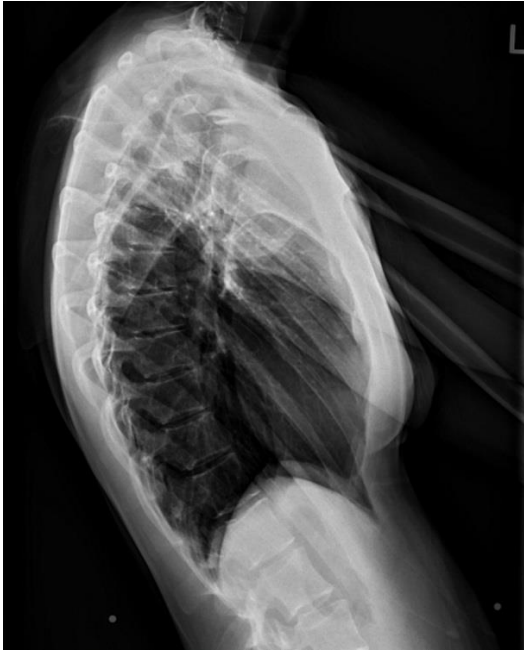**Table 1.** Patient self-rated her physical complaints after 24 chiropractic adjustments.



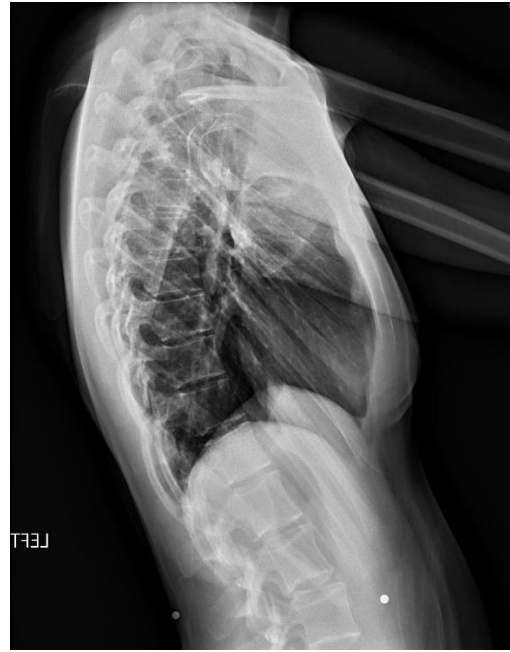**Figure 1:** AP x-ray taken prior to care



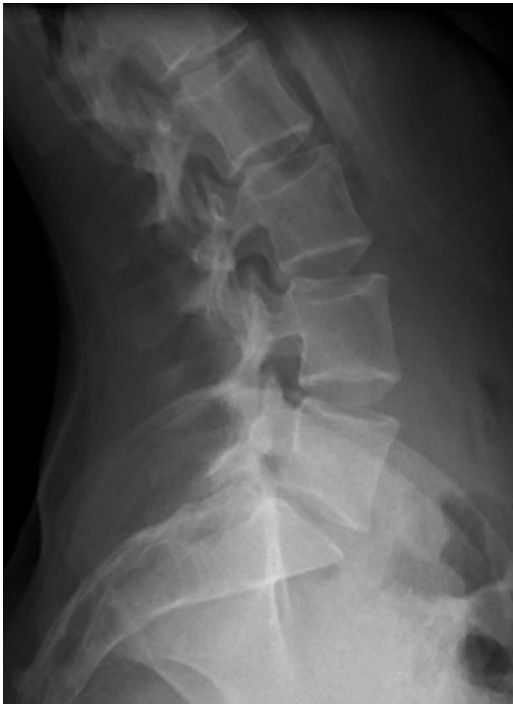**Figure 2:** AP x-ray after 5 mos. of chiropractic care, (62 visits)



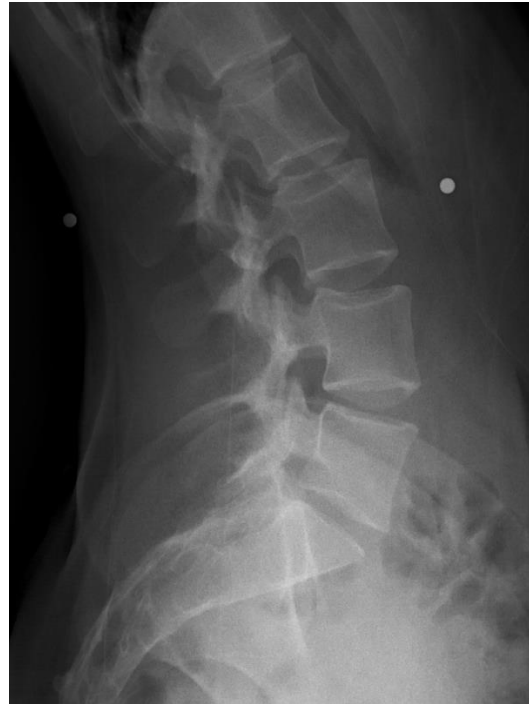**Figure 3:** Lat. thoracic taken prior to care, Nov. 2014.



**Figure 4:** Lat. thoracic after 5 mos. of care, Mar. 2016.



**Figure 5:** Lat. lumbar x-ray taken prior to care, Nov. 2014.



**Figure 6:** Lat. lumbar after 5 mos. of care, Mar. 2016.



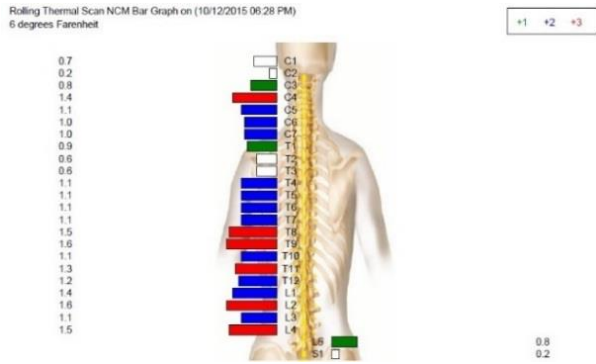


Figure 7: Initial thermal scan.

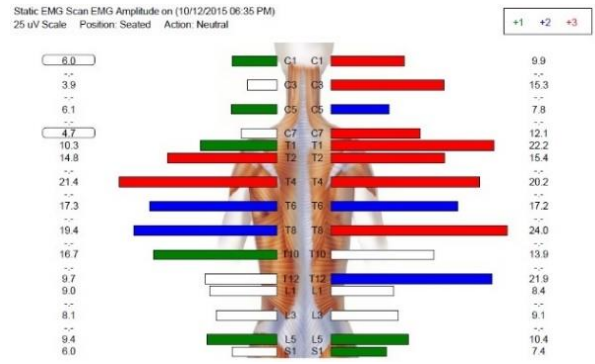


Figure 8: Initial sEMG.

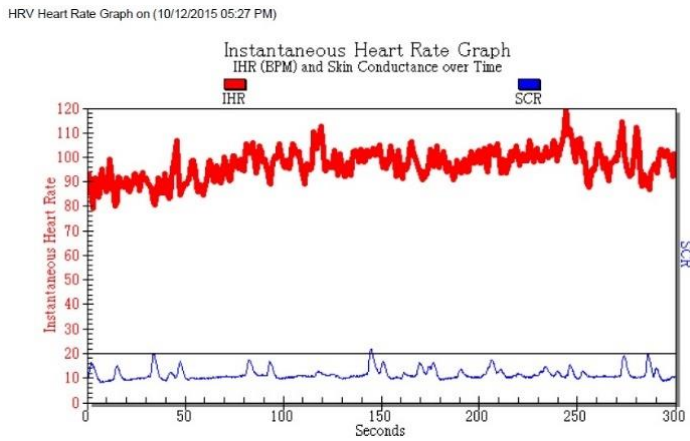


Figure 9: Initial HRV graph.

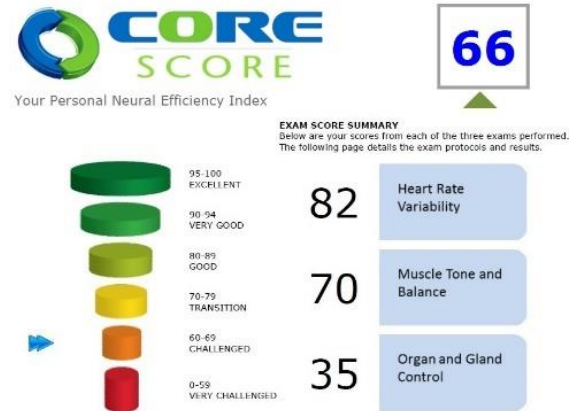


Figure 10: Initial COREscore™/Neural Efficiency Index 66.

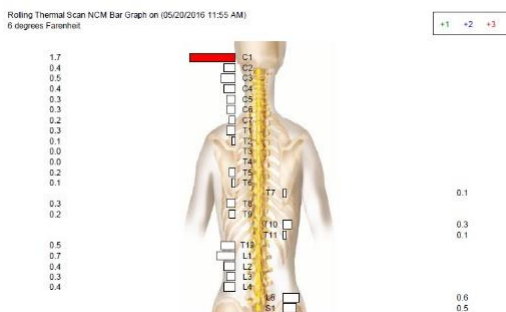


Figure 11: Thermal reading after 7 mos. of care.

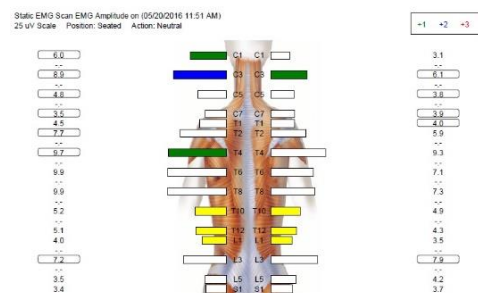
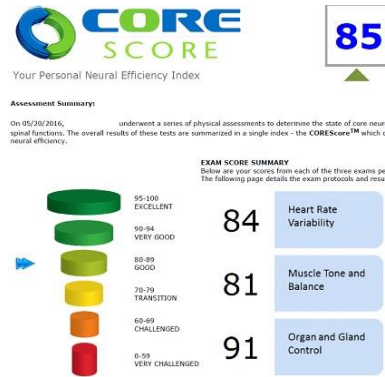
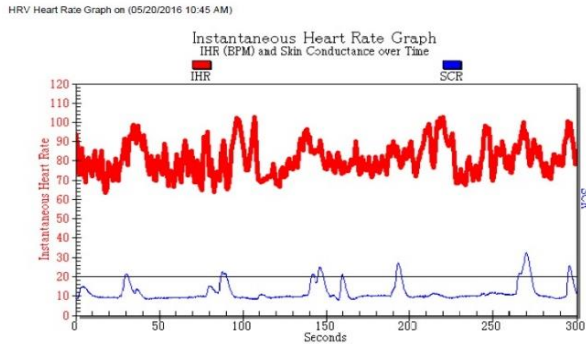
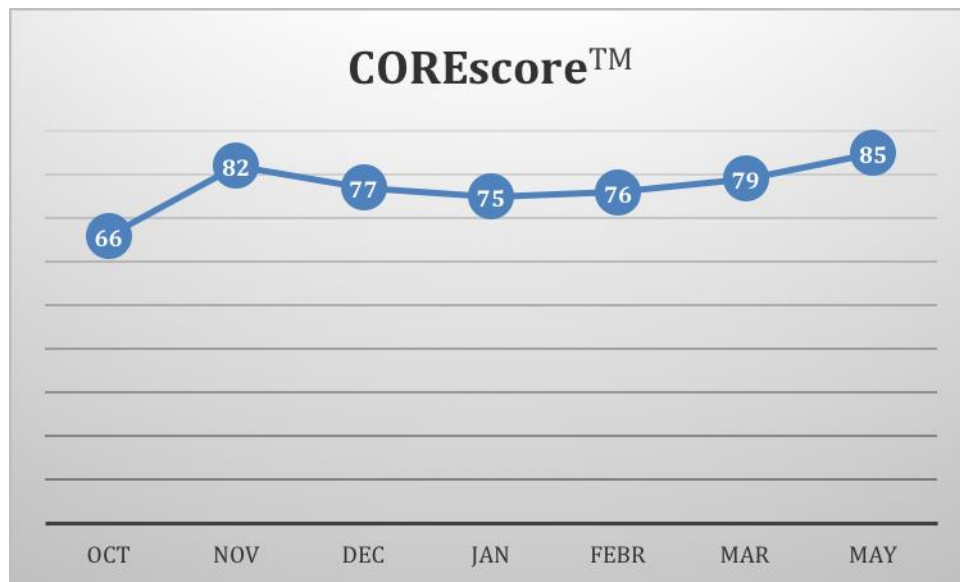

Figure 12: sEMG scan after 7 mos. of care.

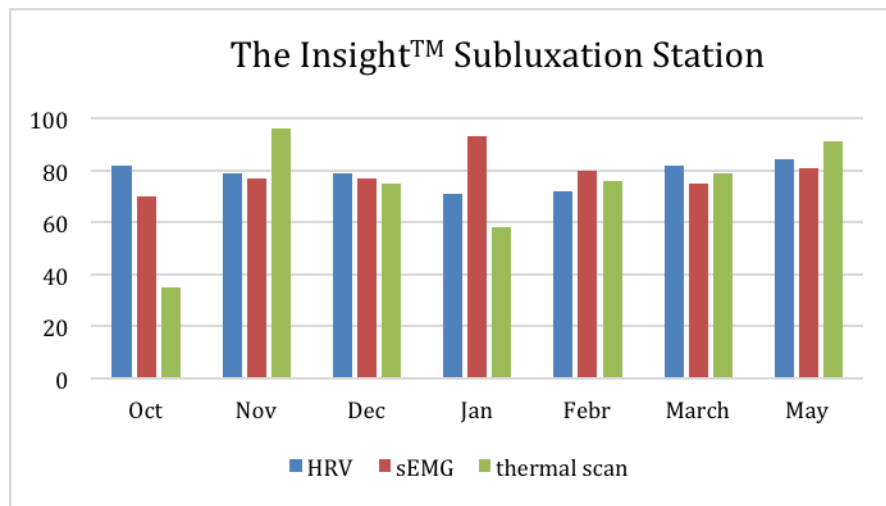


**Figure 13:** HRV after 7 mos. of care.

**Figure 14:** COREscore™ 85 after 7 mos. of care.



**Figure 15:** COREscore™ from initial visit in Oct 2015, measured at each reassessment until end of care, May 2016.



**Figure 16:** Change in HRV, sEMG and thermal scan reading from initial visit in Oct 2015, and at each reassessment until end of care May 2016.